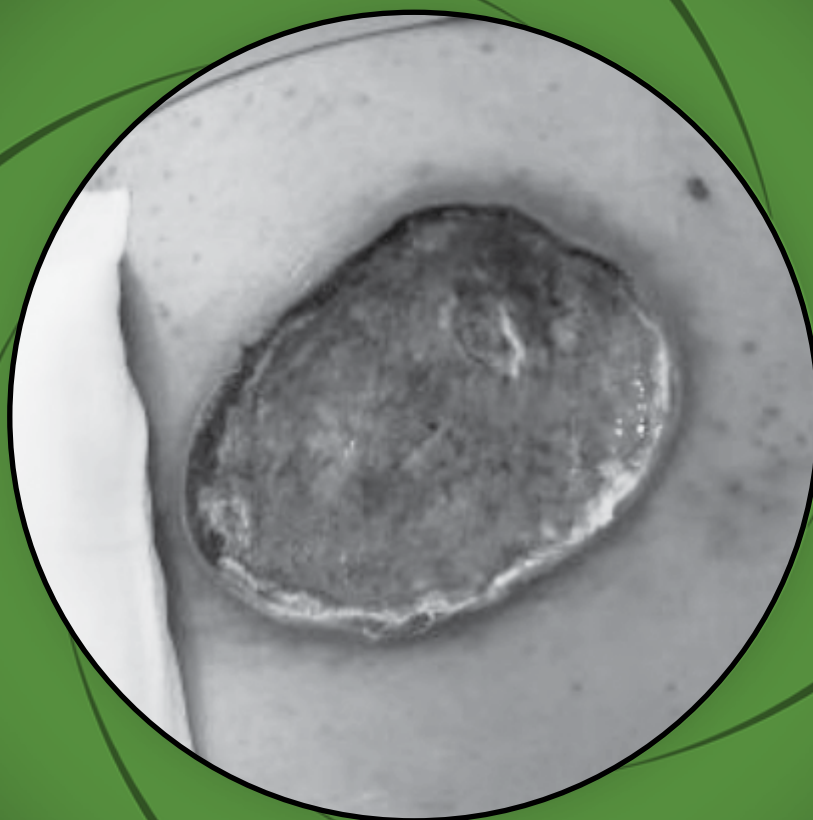


# A Case Report on Usage of Antimicrobial Hydrophilic Polyurethane Foam Matrix (RTD) in A Dressing of A Patient with Metastatic Skin Cancer

MR Mohamad Helmi, L Azura • Wound Unit Hospital Ampang



**GLOBAL WOUND CONFERENCE 2018**

21 - 23 September 2018 • Royale Chulan Kuala Lumpur Jalan Conlay

## Introduction

Metastatic skin cancer will mainly arise from other primary cancer whereby the cancer spreads via hematogenous or lymphatic spread. The commonest primary cause of metastatic cancer can be of any form.

In a patient diagnosed with Acute Myeloid Leukemia, it is pretty much common for them to concurrently diagnosed with myeloid sarcoma which is another type of extra medullary myeloid tumor.<sup>1</sup> And among all the sites involved, skin considered as one of the commonest area for its infestation.<sup>2</sup>

In this case, patient is diagnosed with Acute Myeloid Leukemia and subsequently develop skin infestation over the lower back trunk. Saucerization was done and histopathological result came back as Myeloid Sarcoma.

In managing post surgical wound from an origin of metastatic cancer, extra precautions in type of dressing used need to be highlighted as not all dressings material are suitable. The aim in managing post surgical wound is to make sure no secondary infection, to facilitate in wound closure, reduce incidence of re debridement and return to operation theatre, and a dressing that can be use to reduce the pain. This is because patient with cancerous cells usually in the state of neutropenic and prevention from becoming sepsis is sinister.

As to prevent infection, silver impregnated dressing can be used as most of these dressing are very useful in managing any formation of biofilm which later will cause delay in wound closure. In terms of managing the exudate and to relieve the pain, a foam type of dressing can be use as foam works well in absorbing he excessive exudates and also easy to remove.

## Case report

A 35-year-old gentleman, diagnosed with Acute Myeloid Leukemia and at the same time develop a cutaneous skin lesion over the lower back trunk at the size of 15cm x 10cm. Patient subsequently went for saucerization of what it seems to be a carbuncle. Post saucerization, histopathological examination initially stated that it was squamous cell carcinoma. However, a second look and detailed examination showed that it was conclusive of myeloid tumor in view of the appearance and primary cause of the tumor is Acute Myeloid Leukemia. Post operatively, wound was still appeared sloughy wound bed with erythematous surrounding wound edge. Case was then referred to wound team for co management of the wound. In view of slough tissues, bedside sharp debridement was done carefully as patient has high tendency to bleed in view of thrombocytopenia. Post debridement he was put on silver alginate dressing but the tissue viability remain as a big concern after 1 cycle of usage. Gel dressing was then applied but again wound bed was not promising. And more infective tissues started to come in. Patient was then subjected for ultrasonic debridement and was put on Antimicrobial Hydrophilic Polyurethane Foam Matrix (RTD) and the result was promising and wound healed completely within 6 weeks period.

## Methodology

Wound was cleansed with sterile water and RTD foam applied directly on the wound bed. Wound assessment was done from time to time. Initially patient was put on a combination between hydrogel and RTD foam in view of necrotic patch tissues and evidence of slough tissues. Once no more necrotic patch and slough tissues, RTD foam applied per se directly to the wound bed until secondary wound closure happened.

## Result

Secondary wound closure achieved within 6 weeks without any recurrence of bacterial infection, no bleeding despite of thrombocytopenia, dressing change was non painful as compared to other type of dressing and exudates level manage to be control with the dressing usage.

## Discussion

Antimicrobial hydrophilic Polyurethane foam matrix (RTD) foam serves as high function of absorbent with combination of methylene blue, gentian violet and silver ion that are intergrated to a therapeutic blue foam. The foam has been structured and function in such a way as what it is made of. Methylene blue acts to attract all exudates whether bacteria or dead tissues into the dressing material. Gentian violet function as for antibacterial and antifungal as well as providing analgesic effect. Silver ion alginates function as to kills all the gram positive and negative bacteria as it binds to the cells in the presence of exudates. With all of these, it will promote a healthy wound bed as it clears the exudates, giving a good antimicrobial and antifungal effect, preventing formation of biofilm, non cytotoxic and reduced the burden on pain during dressing. In relation to this case where managing infection considered as a challenge, the foam does works well and helps in assisting the wound bed for skin closure. As in any cases with wound, in order to achieve good epithelialisation, wound bed preparation is mandatory and important so that new cells formation can occur..

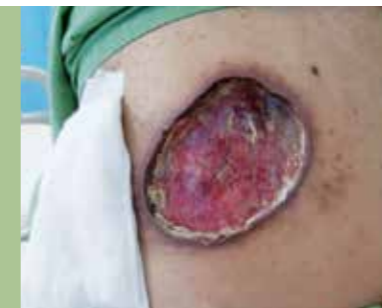## Conclusion

RTD foam should be considered as an option for local control of infection in wounds that showed no response to other type of treatment whether topical or systemic treatment as well.

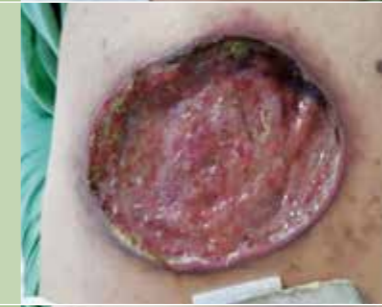## References

1. *Final Diagnosis - Myeloid Sarcoma - UPMC department of pathology.*
2. *Brunning R.D, Bennett J, Matutes E, et al Acute myeloid leukemia not otherwise categorised In: Jaffe E.S, Harris N.L, Stein H, and Vardiman J.W (eds). WHO Classification of Tumours; Pathology and Genetics of Tumours of Haematopoietic and Lymphoid Tissues. IARC Press, Lyon 2001:pages 104-105.*

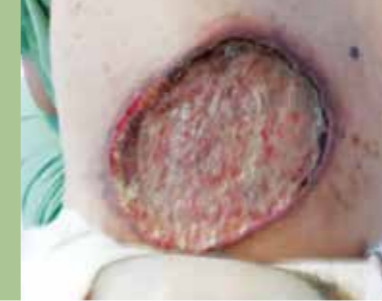Initial state of wound



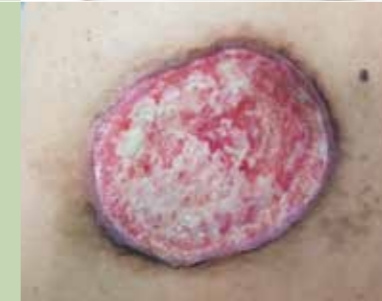After 3 days of silver alginate dressing



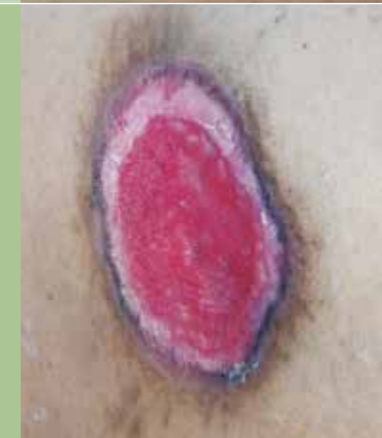Prior to ultrasonic debridement and RTD foam



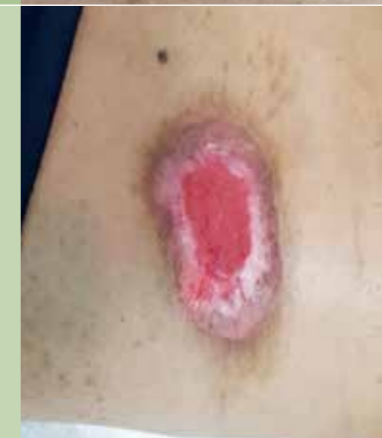After 2 weeks usage of RTD foam



After 6 weeks usage of RTD foam



After 1 month usage of RTD foam



KUALA LUMPUR

GLOBAL WOUND CONFERENCE 2018

*Presentation supported by:*



**SOZA HEALTHCARE Sdn Bhd** (1001759-X)

Suite 102, E111 Block E, Phileo Damansara 1, No.9, Jalan 16/11,  
Off Jalan Damansara, 46350 Petaling Jaya, Selangor D. E., Malaysia  
Tel: 03-7493 5176 Fax: 03-7493 5100 Website: [www.soza.com.my](http://www.soza.com.my)

*Exclusive distributor for:*



**KENERIC HEALTHCARE, USA**

**KENERIC**  
HEALTHCARE